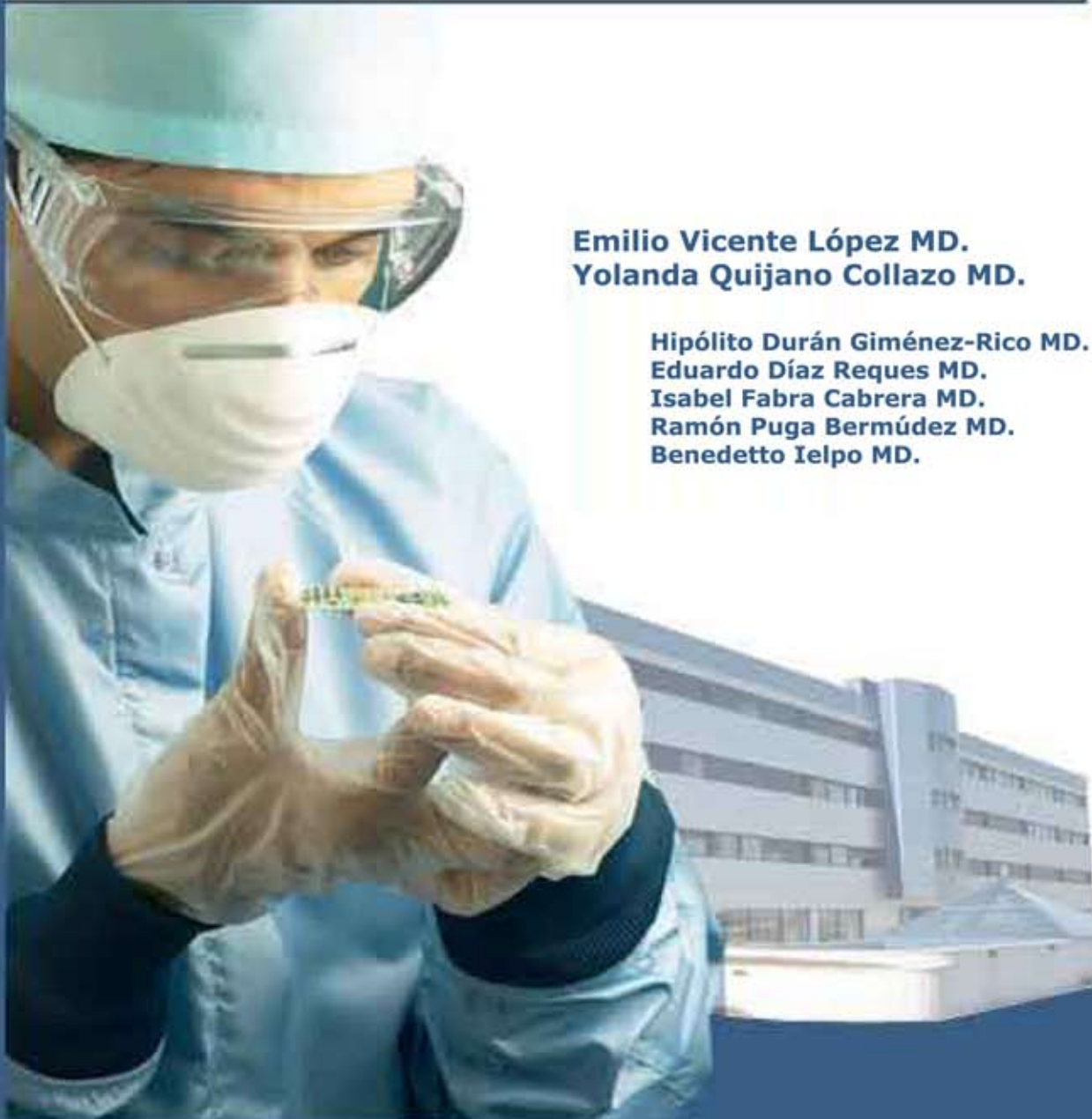




General and Digestive Surgery Department

Parenchyma preparation for extended liver surgery

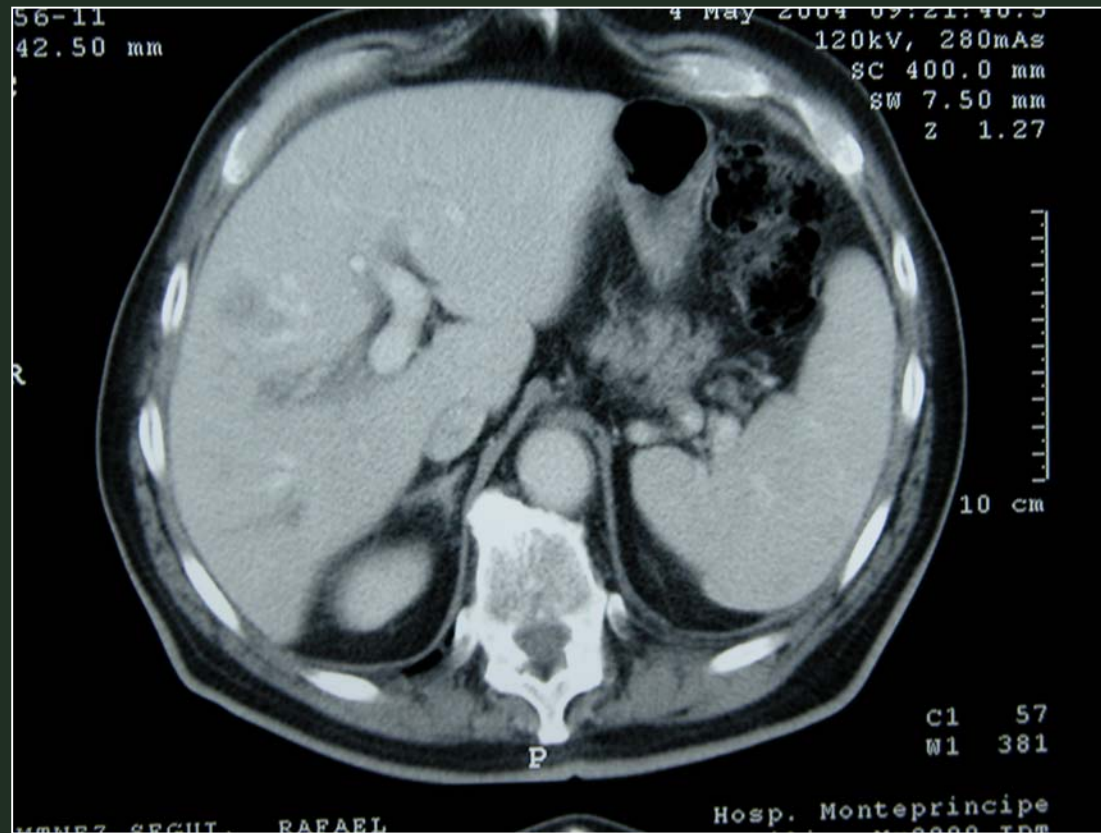
Clinical case:
**Liver metastasis from colorectal carcinoma in
78-year-old patient**



Emilio Vicente López MD.
Yolanda Quijano Collazo MD.

Hipólito Durán Giménez-Rico MD.
Eduardo Díaz Reques MD.
Isabel Fabra Cabrera MD.
Ramón Puga Bermúdez MD.
Benedetto Ielpo MD.

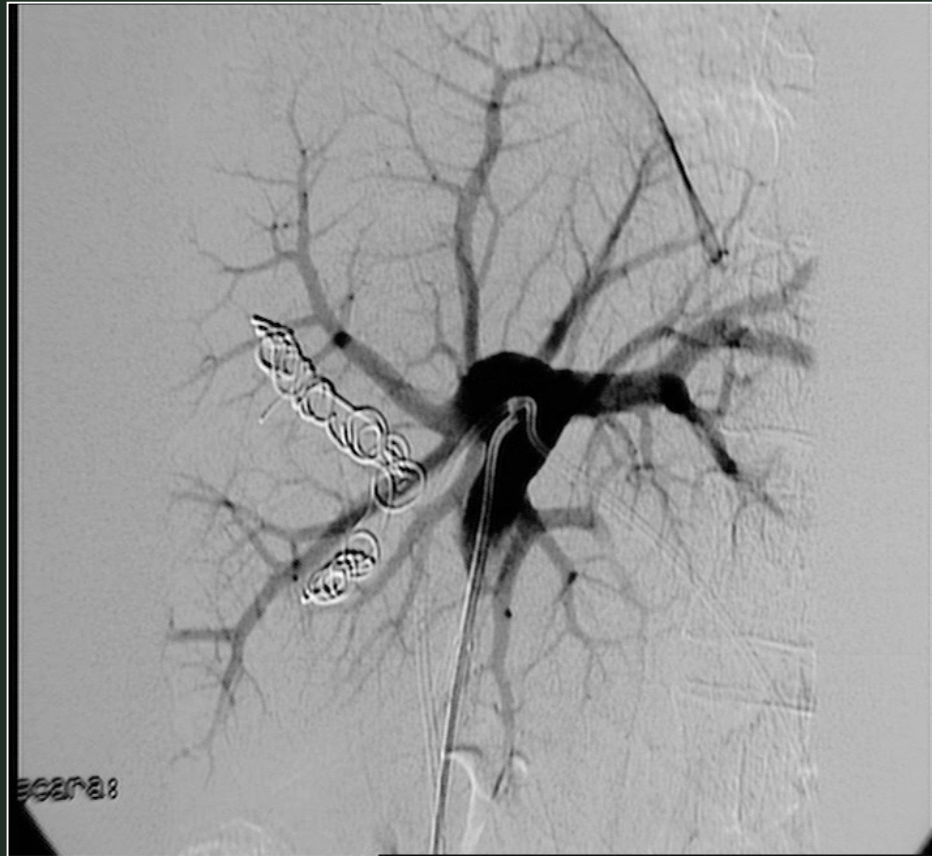
PARENCHYMA PREPARATION FOR EXTENDED LIVER SURGERY



**Liver metastasis from colorectal carcinoma in
78 -year-old patient**



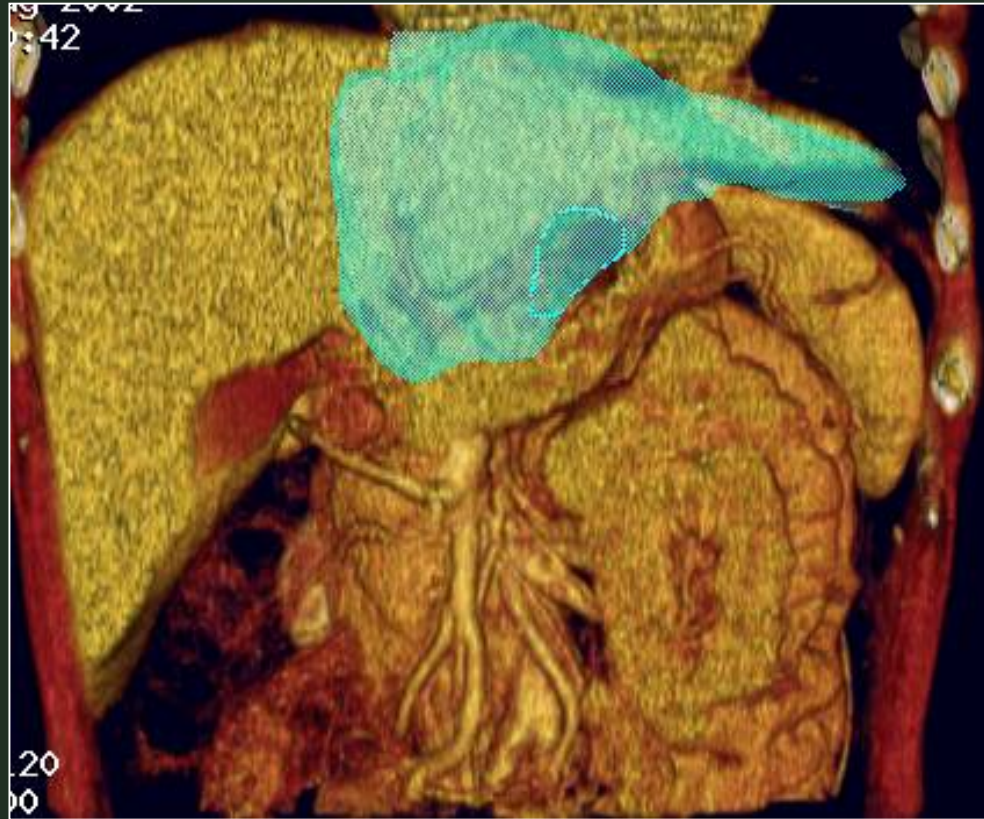
PARENCHYMA PREPARATION FOR EXTENDED LIVER SURGERY



Preoperative portal embolization



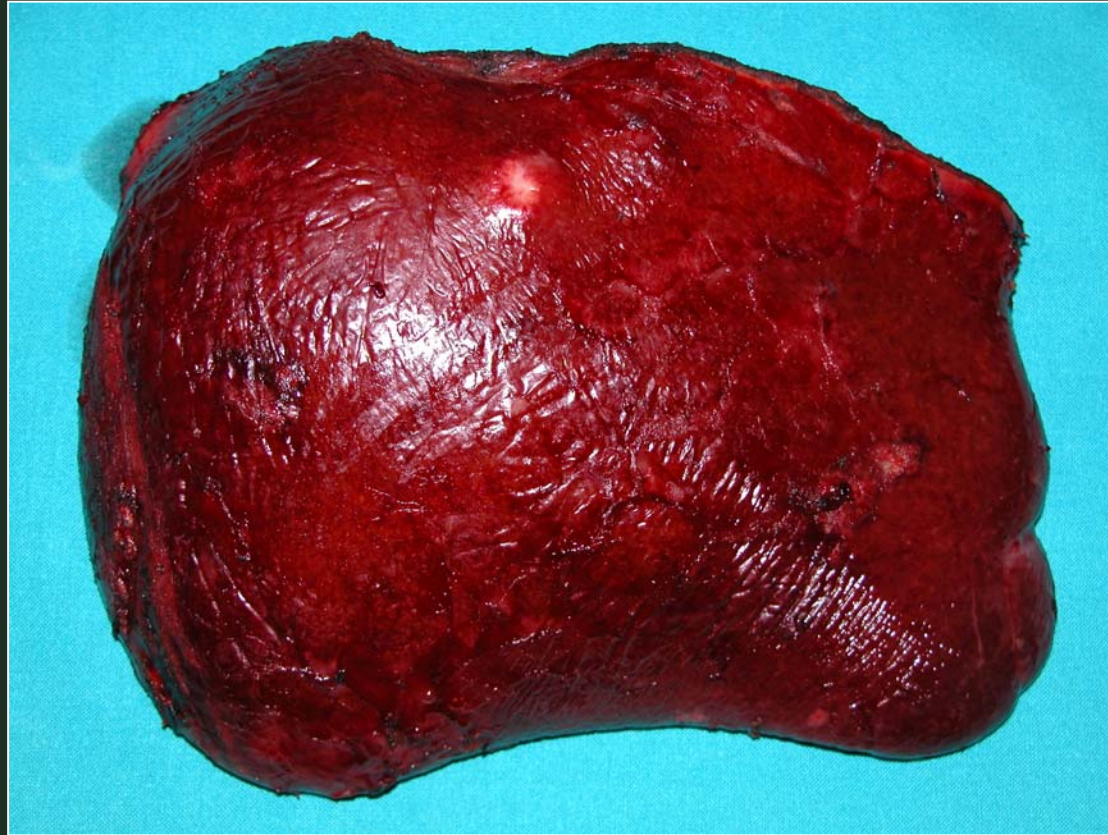
PARENCHYMA PREPARATION FOR EXTENDED LIVER SURGERY



Liver remaining volume after the portal
embolization



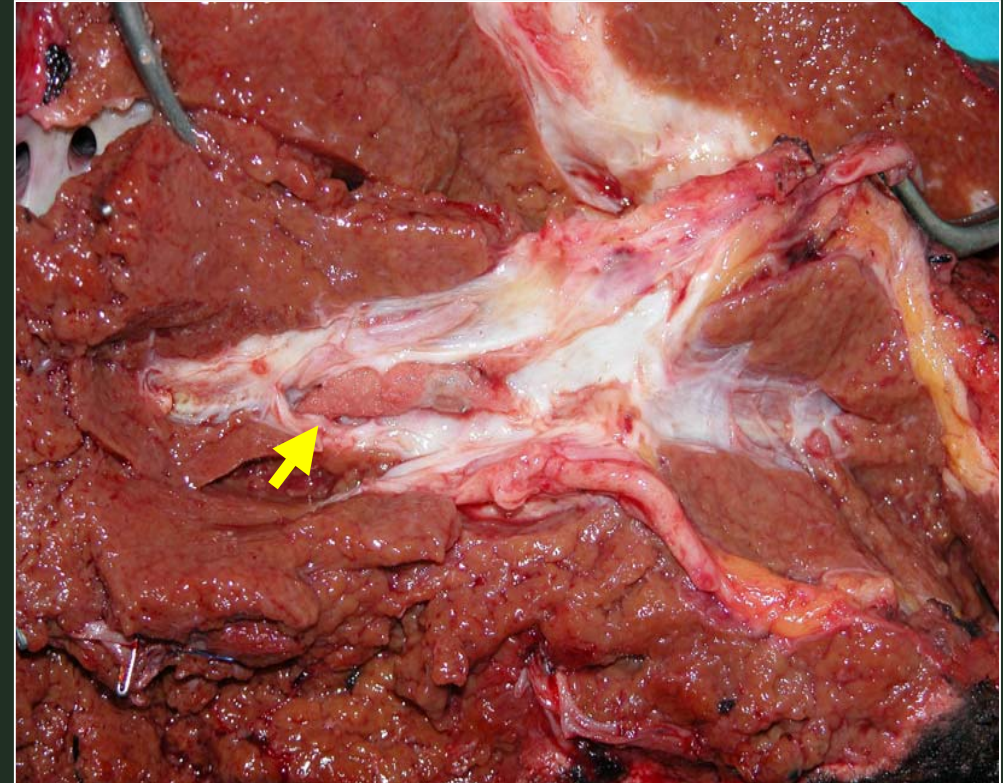
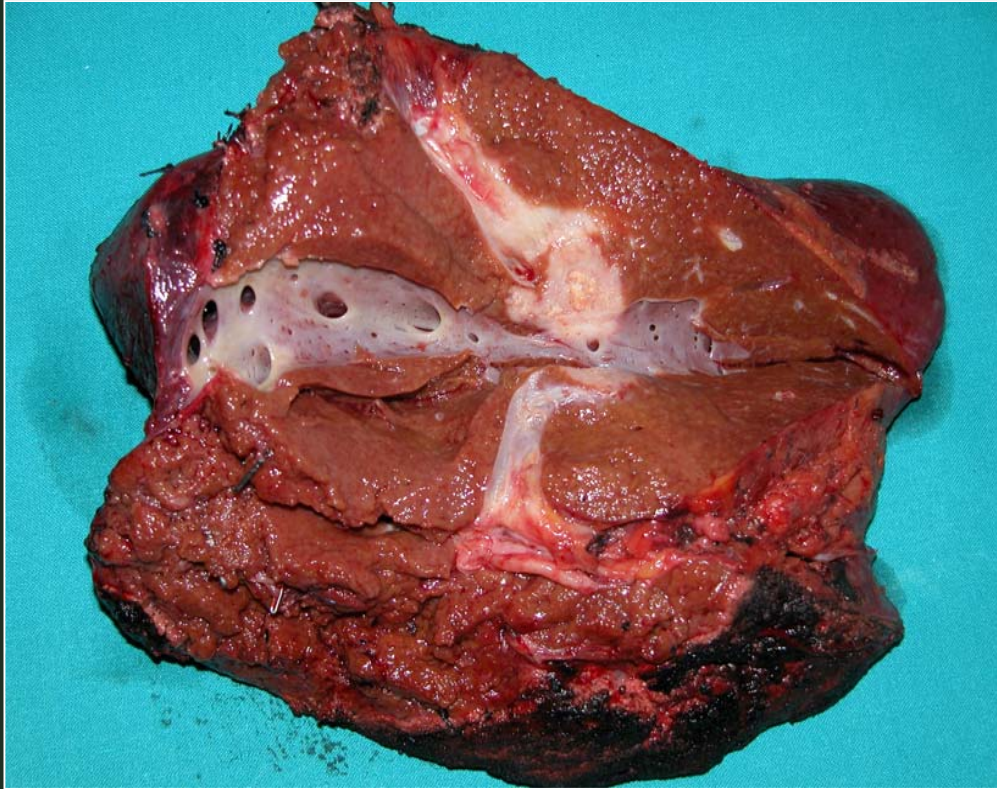
PARENCHYMA PREPARATION FOR EXTENDED LIVER SURGERY



Right liver resection, Segments V, VI, VII y VIII



PARENCHYMA PREPARATION FOR EXTENDED LIVER SURGERY



Liver metastasis in intimate proximity with the right liver vein.
Embolization material located in right portal vein

